



PATIENT

Cassie Davison

SPECIES

Canine

BREED

Miniature Pinscher

SEX

Female Spayed

AGE

13 years

WEIGHT

11lbs

INTERPRETED BY

Maggie Machen Lamy,
DVM, DACVIM
(Cardiology)

IMAGING PERFORMED BY

Loetitia St-Jacques,
LVT/RVT

HOSPITAL NAME

Dr. Carrie McCraw

REFERRING VET

Dr. McCraw

PRESENTING CLINICAL SIGNS

History: Chronic cough currently sounds wet (per owner), mainly in AM, but occasional coughs throughout the day. Has had prior episodes of presumed pneumonia resolved with antibiotics. Bilateral pulmonary crackles.

-Current medications: Thyro Tabs 0.1mg- 1.5 tablets PO q24h, Theophylline 50mg/ml- 1 ml PO q24h, Gabapentin 250mg/5 ml- 0.5ml PO q12h, Cerenia 60mg- 1/4 tablet PO q72h.

ECHOCARDIOGRAM FINDINGS

2D, m-mode, color flow and doppler imaging is available. Normal mitral valve leaflets with no prolapse into the left atrial lumen. No mitral regurgitation with no left atrial dilation. Normal LV diameter with adequate myocardial function. The tricuspid valve appears normal with no obvious tricuspid regurgitation. Normal right atrial and ventricular diameter and morphology indicating no overt evidence of pulmonary arterial hypertension. The pulmonic and aortic valves are normal in morphology and mobility. Normal pulmonic and aortic outflow velocities with laminar flow. No obvious aortic or pulmonic insufficiency. No pericardial or pleural effusion noted. No obvious cardiac masses.

CARDIAC CHART

CANINE CARDIAC PARAMETERS	MR VMAX (m/s)	TR VMAX (m/s)	LA/AO (Boon method)	LA/AO (Heart Base; Swe)	FS (%)	EF (%)	EPSS (cm)
NORMAL PARAMETER	4.5-5.5	<2.7	1.3	<1.6	28-40	40-100	<0.6
PATIENT	NA	NA	NM	1.2	50	84	NM
CANINE CARDIAC PARAMETERS	HR (BPM)	AV VMAX (m/s)	PV MAX (m/s)	BODY WEIGHT (kg)	LA 2D short axis Base view (cm)	LVIDd Avg; 2D and m-mode short axis (cm)	LVIDs Avg; 2D and m-mode short axis (cm)
NORMAL PARAMETER	50-100	0.7-1.7	0.7-1.6	BELOW	BELOW	BELOW	BELOW
PATIENT	NM	1.3	1.3	5.0	1.3	2.4	1.2
*Normal chamber parameters expressed as a mean value (SD)				3	1.27 (5.3)	2.46 (2.46)	1.36 (5.5)
BODY WEIGHT DEPENDENT PARAMETERS				5	1.40 (4.5)	2.74 (5.2)	1.60 (4.7)
<i>*Note: All measurements based upon multi-modal images and methods. An average value is reported.</i>				10	1.50 (3.8)	3.27 (3.5)	2.06 (3.1)
				15	1.83 (2.0)	3.71 (2.4)	2.43 (2.1)
				20	2.02 (1.9)	4.14 (2.2)	2.80 (2.0)
				25	2.18 (2.4)	4.48 (2.9)	3.10 (2.5)
				30	2.33 (3.3)	4.83 (3.9)	3.39 (3.4)
				35	2.48 (4.3)	5.17 (5.0)	3.69 (4.5)
				40	2.62 (5.2)	5.48 (6.1)	3.96 (5.4)
				50	2.88 (7.1)	6.07 (8.3)	4.46 (7.4)

INTERPRETATION OF THE FINDINGS & FURTHER RECOMMENDATIONS

Overtly normal cardiac dimensions and function, with no obvious dysfunction or dilation of the left heart. No significant valvular leaks are visualized, and no evidence of pulmonary hypertension.

INVOICE

29819

DATE

323/23

No cardiac medications are indicated at this time as the cough appears non-cardiac in origin. Continued work up for infectious/inflammatory respiratory causes is recommended. Options



PATIENT

Cassie Davison

SPECIES

Canine

BREED

Miniature Pinscher

SEX

Female Spayed

AGE

13 years

WEIGHT

11lbs

INTERPRETED BY

Maggie Machen Lamy,
DVM, DACVIM
(Cardiology)

IMAGING PERFORMED BY

Loetitia St-Jacques,
LVT/RVT

HOSPITAL NAME

Dr. Carrie McCraw

REFERRING VET

Dr. McCraw

INVOICE

29819

DATE

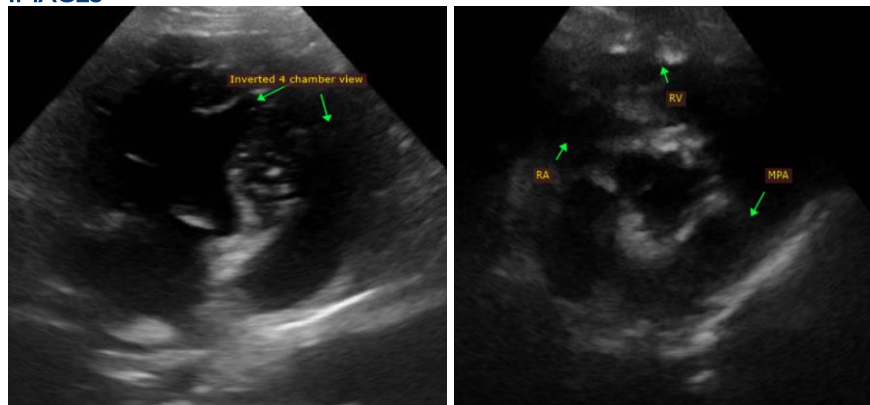
3/23/23

include Baytril or similar antibiotic, anti-inflammatory prednisone, aggressive hydrocodone, etc. If refractory, may consider TTW/BAL for further information.

Monitor for development of a heart murmur, cough, labored breathing, exercise intolerance or collapse episodes.

Chronic respiratory issues can lead to pulmonary hypertension if poorly controlled and a recheck echocardiogram is recommended should any exertional syncope/dyspnea occur, or a murmur be noted in the future.

IMAGES



The information and recommendations provided are based on the images presented by the referring veterinarian. No evaluation can be communicated regarding pathology that was not visible in the image/video clips provided.

Thank you for this referral. This report was generated using transcription software, and minor dictation errors may be present. If the clinical or image interpretation does not parallel your findings or if I can be of any further assistance, please contact me.

Maggie Machen Lamy, DVM
Diplomate of the American College of Veterinary Internal Medicine (Cardiology)
info@sonopath.com